

ABSTRACTS PAUSE 14:15

TABLE OF CONTENTS

LEPTOSPIROSIS AND HANTA VIRUS INFECTION IN PATIENTS WITH ACUTE DENGUE FEVER IN THE WESTERN PROVINCE, SRI LANKA..... 2

LEPTOSPIROSIS IN ALBANIA..... 3

PRESENTATION OF LEPTOSPIRES FORMING BIOFILM IN THE VITREOUS CAVITY OF HORSES SUFFERING FROM RECURRENT LEPTOSPIRAL UVEITIS..... 5

ADHATODA VASICA: POTENTIAL CANDIDATE FOR TREATMENT OF EQUINE LEPTOSPIROSIS..... 8

LEPTOSPIRA INTERROGANS SEROGROUP POMONA IN SICILIAN WILD BOARS (*SUS SCROFA*) 9

ORGANIZATION OF ANIMAL LEPTOSPIROSIS DIAGNOSTIC STUDIES IN THE RUSSIAN FEDERATION...10

LEPTOSPIROSIS AND HANTA VIRUS INFECTION IN PATIENTS WITH ACUTE DENGUE FEVER IN THE WESTERN PROVINCE, SRI LANKA

Samarakoon P. S. M. J. U.¹, Karunanayake Lilani², Muthugala M. A. R. V.³, Dheerasekara W. K. H.³, Karunanayake S. A. A. P.⁴

¹Postgraduate Institute of Medicine, University of Colombo, Colombo, Sri Lanka.

²Department of Bacteriology, Medical Research Institute, Colombo, Sri Lanka.

³Department of Virology, Kandy National Hospital, Kandy, Sri Lanka.

⁴Department of Clinical Medicine, Faculty of Medicine, University of Colombo & Professorial Unit, National Hospital of Sri Lanka, Colombo, Sri Lanka

Introduction and Objectives

Dengue fever, leptospirosis and hantavirus infection share common clinical manifestations. They are regarded as potentially life-threatening illnesses. We aim to determine the prevalence of leptospirosis and hantavirus infection (HVI) among acute dengue fever (ADF) patients.

Methods

Descriptive cross-sectional study was carried out in 5 hospitals in the Western Province, Sri Lanka between December 2018 to April 2019. Venous blood was collected from adult patients clinically-diagnosed as ADF.

ADF was confirmed by DENV NS1-antigen-ELISA, IgM-ELISA, IgG-ELISA and IgG quantification assay. Leptospirosis was confirmed by Microscopic agglutination test and *Leptospira* Realtime PCR. HVI was determined serologically by IgM-ELISA. Interviewer-administered questionnaire was used to collect socio-demographic and clinical data.

Results

Study was conducted in 386 adult patients managed as ADF. Median age was 29 years with male predominance. Among them, 297 (76.9%) was laboratory-confirmed as ADF and 1.6% had only leptospirosis.

Among the 297 laboratory-confirmed ADF patients, 23 (7.74%) had leptospirosis and 6 (2%) had HVI.

Fever was the commonest symptom in the study group. Myalgia was significantly common in ADF. In the leptospirosis-dengue group, majority (65.2%) were females. Exposure history in leptospirosis was present in 62.1%. Majority (69.5%) had WBC <5000X10⁶/L and 19 (82.6%) had thrombocytopenia (<150X10⁹/L).

In HVI-dengue group, majority (83.3%) had myalgia and arthralgia. Thrombocytopenia was present in all patients.

Conclusions

Among ADF patients, prevalence of concomitant leptospirosis was 7.74% and hantavirus infection was 2%. Attention to other etiological agents during dengue fever outbreaks is vital as they share similar clinical presentations.

LEPTOSPIROSIS IN ALBANIA

Erjona Abazaj¹; Luljeta Alla¹; Edmond Puca²; Ela Ali² Oltiana Petri¹; Silva Bino¹

¹Institute of Public Health, Tirana, Albania

²Service of Infection Diseases, University Hospital Center "Mother Theresa", Tirana, Albania

Introduction

Leptospirosis is one of the most widely distribution zoonotic infection in worldwide. In Albania, Leptospirosis is a disease under diagnosed & under reported due to lack of distinguishing clinical signs from those other endemic diseases, lack of epidemiologic information and a lack of appropriate diagnostic laboratory services. The aim study is to evaluate the prevalence and incidence of leptospirosis during last decade, and to examine the relationship between disease and other variables of interest.

Methods

This is a retrospective study conducted from 2010-September 2020 based to laboratory and surveillance systems. A total of 720 samples were analysed from patients attending a reference Albanian`s hospital. The conventional ELISA test were performed for estimation of IgM and IgG antibodies in all cases. The software SPSS version 20.0 were used to analysed data.

Results

Over all 720 sera from hospitalized patients, the prevalence of acute Leptospirosis cases resulted 37.2% and the incidence Rate = 0.958 per 100.000 pop. Over ten years the average of cases resulted 29.1 cases/year (ranges of cases/years was 10 to 41). Male were 595 (82.64%) of them and female were 125 (17.36%). Our study demonstrates that men are more affected than women by this infection, due to occupational exposure for CI 95% odds ratio [1.07-2.34] p value 0.02. The average age was 51.36 ± 13.81 with min 19 and max 85 years old. The most predominant age groups were 41-50 years and 51+ years old. The number of leptospirosis cases peaked during the rainy season and a significantly associated were seen between the heavy rainfall and number of hospitalized cases (CI 95%; $p < 0.05$).

Conclusion

This retrospective study reveals a marked increase of cases during those ten years. Flooding and heavy rainfall have been associated with an increase of leptospirosis in Albania, so nowadays Leptospirosis should receive the attention of the stakeholders for prevention and evaluation of situation. We need to implement and to increase the access to more sensitive and specific diagnostic methods needed to complete a final confirmed diagnose and provide information about circulating serovars in Albania.

Keywords: Leptospirosis, prevalence, Albania

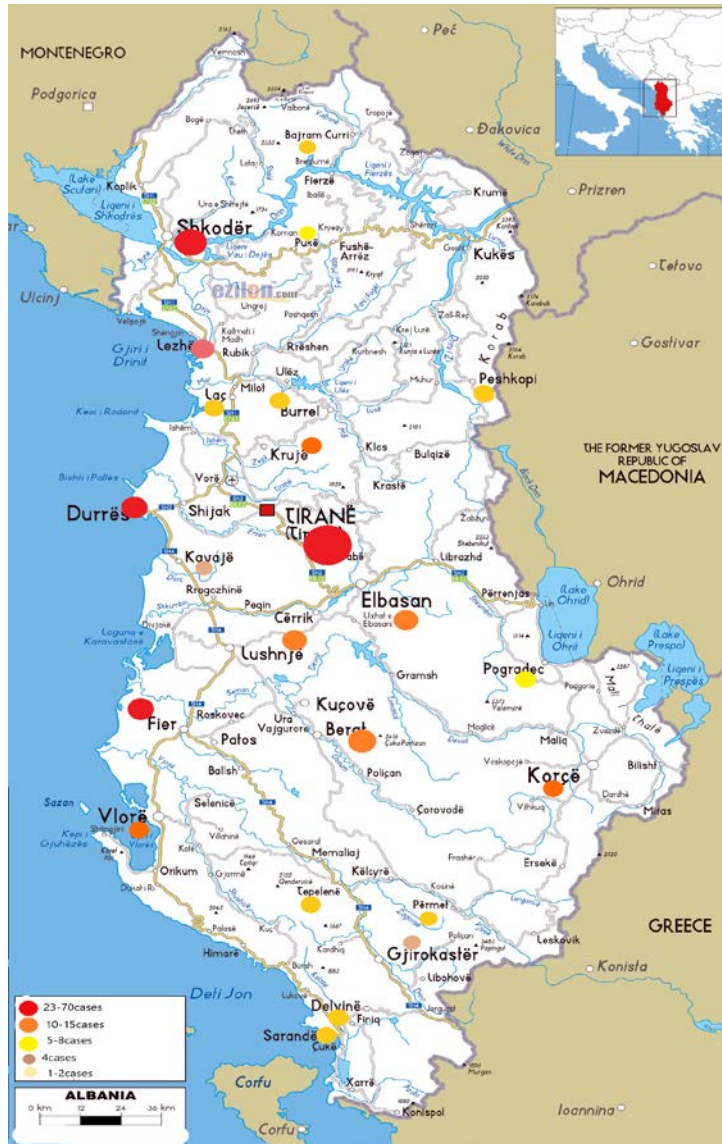

Figure 1. Map of positivity cases by the city

E-Mail of presenting author: abazajerjona@gmail.com

PRESENTATION OF LEPTOSPIRES FORMING BIOFILM IN THE VITREOUS CAVITY OF HORSES SUFFERING FROM RECURRENT LEPTOSPIRAL UVEITIS

Kerstin Ackermann¹, Rebecca Kenngott², Bettina Wollanke¹

¹Equine Clinic, Faculty of Veterinary Medicine, Ludwig-Maximilians-University Munich, Veterinaerstr. 13, 80539 Munich

²Institute of Veterinary Anatomy, Histology and Embryology, Ludwig-Maximilians-University Munich, Veterinaerstr. 13, 80539 Munich

Introduction

In horses suffering from the typical form of recurrent uveitis, a chronic intraocular leptospiral infection is detectable by an intraocular antibody production (MAT and ELISA-tests positive in > 90 % of vitreous samples), PCR targeting e.g. LipL32 (positive in 70 % of vitreous samples) and culture with vitreous samples (positive in > 50 %). During the leptospiral infection, autoimmune reactions are detectable. Lavage of the vitreous cavity and removal of the intraocular leptospiral infection, vitreous haze, floaters and fibres with the two-port pars plana vitrectomy can stop the uveitis recurrences very effectively. Earlier ultrastructural studies revealed a biofilm-like structure around the leptospires and spherical structures of an unknown origin. The immune-privilege of the eye, the large vitreous cavity in horses (30 ml) and the vitreous fibres, which could serve as boundary surfaces, might favour the chronic infection and in vivo biofilm formation. Aim of this study was to look for biofilm formation in equine vitreous samples from eyes with florid infections before severe atrophy of the eyeball and blindness occur.

Methods

The samples were prepared for two staining methods. Warthin-Starry staining and Immunohistochemistry (IHC) were used for the display of leptospires and the biofilm.

Results

Leptospira spp. could be detected as single bacteria, but also in cyst-like structures by the silvering technique as well as in immunohistochemistry. Especially with immunohistochemistry, the leptospiral structures in different configurations and stages of biofilm formation could be shown.

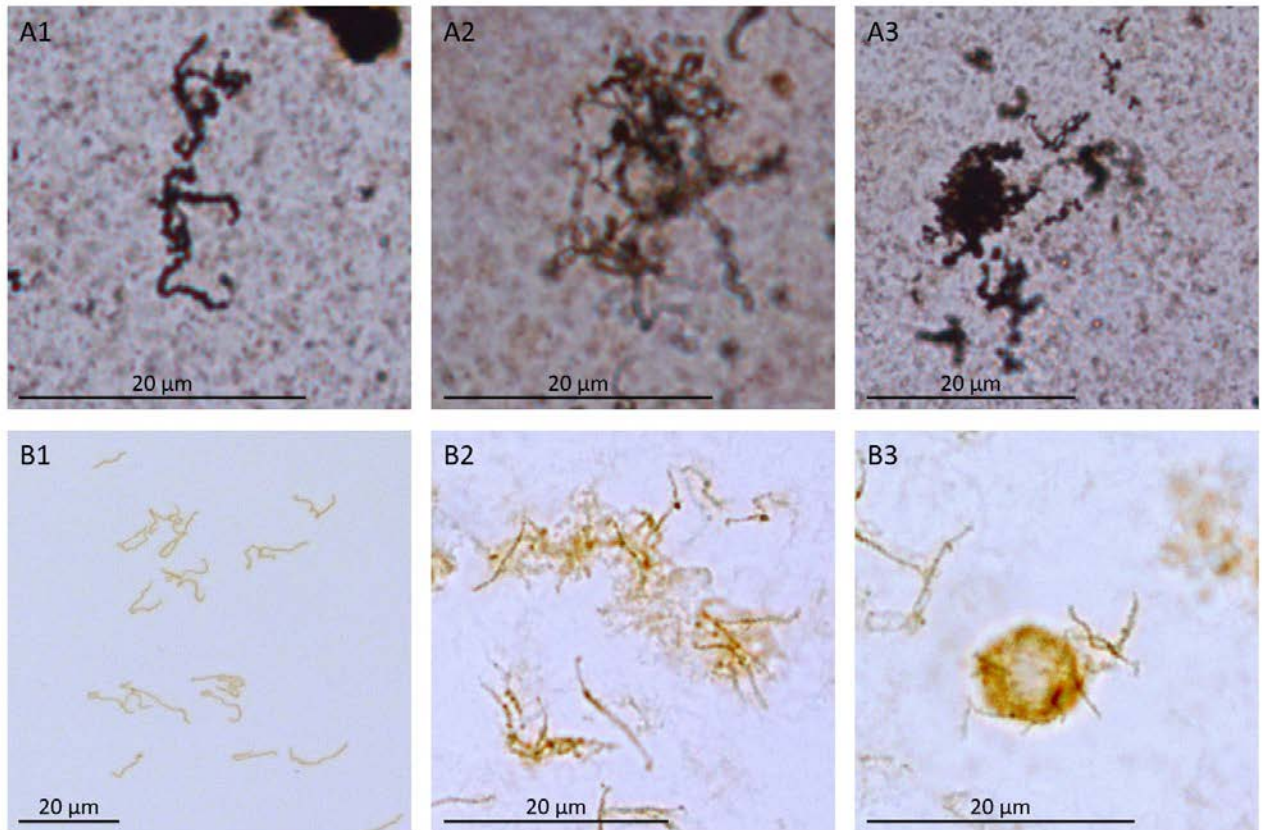


Fig.: 1: different stages of leptospires forming biofilm in vitreous samples of horses
 A= Warthin Starry Staining, B= Immunohistochemistry
 1: single leptospires; 2: micro-colony formation; 3: maturation of biofilm

Conclusion

There is evidence of an intravitreal biofilm production. Biofilm formation around the vitreous fibres and the *Leptospira* spp. is one explanation for the long-term persistence of the bacteria in the vitreous cavity by evading the host's defence mechanisms and for ineffective antibiotic treatment. Furthermore, biofilm formation can explain the high percentage of positive culture results, despite the presence of high intraocular antibody levels and immunocompetent cells.

References

Ackermann K. (foreseen 2021): Darstellung von Leptospiren und deren Biofilmbildung in Glaskörperproben aus an Equiner Rezidivierender Uveitis (ERU) erkrankten Augen. Ludwig-Maximilians-University, Munich.

Brandes K., Wollanke B., Niedermaier G., Brem S., Gerhards H. (2007): Recurrent Uveitis in Horses: Vitreal Examinations with Ultrastructural Detection of Leptospires. *J. Vet. Med. A Physiol Pathol Clin Med* 54(5), 270–275.

Geißler P. K. (2021): Biofilm-Bildung als Pathogenitätsmechanismus bei persistierenden Infektionen und ihre mögliche Rolle bei der Equinen Rezidivierenden Uveitis. Ludwig-Maximilians-University, Munich.

Jamal M., Ahmad W., Andleeb S., Jalil F., et al. (2018): Bacterial biofilm and associated infections. *J Chin Med Assoc* 81(1), 7-11.

Niedermaier G., Wollanke B., Hoffmann R., Brem S., Gerhards H. (2006): Detection of leptospira in the vitreous body of horses without ocular diseases and of horses with ERU using transmission-electron microscopy. Dtsch. tierarztl. Wschr. 113(11), 418-422.

Ristow P., Bourhy P., Kerneis S., Schmitt C., Prevost M.-C., Lilenbaum W., Picardeau M. (2008): Biofilm formation by saprophytic and pathogenic leptospire. Microbiol. 154, 1309–1317.

Wollanke B., Rohrbach B. W., Gerhards H. (2001): Serum and vitreous humor antibody titers in and isolation of *Leptospira interrogans* from horses with recurrent uveitis. J. Am. Vet. Med. Assoc. 219(6), 795-800.

E-Mail of presenting author: Kerstin.Ackermann@pferd.vetmed.uni-muenchen.de

***ADHATODA VASICA*: POTENTIAL CANDIDATE FOR TREATMENT OF EQUINE LEPTOSPIROSIS.**

Muhammad Luqman Sohail¹, Omer Naseer¹, Kashif Hussain¹, Muhammad Shahid², Ameer Hamza Rabban², Yasir Razzaq Khan¹, Ahmad Ali¹, Waqas Ahmad³, Zahida Fatima⁴

¹ Department of Medicine, Cholistan University of Veterinary and Animal Sciences, Bahawalpur, Pakistan

² Department of Surgery, Cholistan University of Veterinary and Animal Sciences, Bahawalpur, Pakistan

³ Department of Theriogenology, University of Veterinary and Animal Sciences, Lahore, Pakistan

⁴ Animal Sciences Division, National Agricultural Research Council, Islamabad, Pakistan

Leptospirosis is a zoonotic disease with worldwide distribution effecting horses along with other animal species. Unfortunately, no comprehensive treatment regimens have been reported for leptospirosis in horses, and are treated by exploring treatment protocol of other species. This study is first in-vivo study, conducted to explore potential of methanolic extract of *Adhatoda vasica* (AV) in alleviating *Leptospira* induced clinicopathological changes in horses. For this purpose, 9 PCR positive horses were treated with methanolic extract of AV, while 9 healthy horses were kept as control. Blood profile, serum biochemical and mineral analysis were performed at day 0 (pre-treatment), 7, 21 and 35 (post-treatment). Results showed statistically significant alterations in all the tested parameters after AV treatment of diseased horses. In diseased horses, RBC, PCV, Hb, MCHC, platelets, Na, K, Mg, Ca, P, Zn, and Cu decreased when compared to control group and were increased after oral AV treatment, while TLC, eosinophils, neutrophils, basophils, lymphocytes, monocytes, MCV, RDW, ALT, AST, ALP, BUN and creatinine increased during leptospirosis and were decreased when, treated with methanolic extract of AV. After 35 days, no significant difference ($P>0.05$) was found between clinicopathological parameters of treated group and control group which highlight role of AV in alleviating *Leptospira* induced clinicopathological alterations. Further exploration of the pharmacodynamics of herb will be a massive breakthrough towards establishment of specific treatment for equine leptospirosis.

E-Mail of presenting author: mluqmansohail@civas.edu.pk

LEPTOSPIRA INTERROGANS SEROGROUP POMONA IN SICILIAN WILD BOARS (*SUS SCROFA*)

Valeria Blanda¹, Giusi Macaluso¹, Francesca Arcuri¹, Anna Candela¹, Rosalia D'Agostino¹, Ilenia Giacchino¹, Mario D'Incau², Domenico Vicari¹, Alessandra Torina¹, Francesca Grippi¹

¹Istituto Zooprofilattico Sperimentale della Sicilia, Palermo, Italy; ²Istituto Zooprofilattico Sperimentale della Lombardia ed Emilia Romagna, Brescia, Italy

Leptospirosis is an infectious, contagious disease caused by pathogenic *Leptospira* species. This zoonotic disease shows a worldwide distribution due to a wide host variety able to maintain or spread the infection. Wild boars (*Sus scrofa*), whose population is constantly increasing all over Europe, represent an important host for *Leptospira*.

This study was aimed at detection and characterization of *Leptospira* species in Sicilian wild boars collected within the wild swine containment plan of the "Ente Parco delle Madonie", during the years 2020-2021.

DNA was extracted from kidneys of five animals and a Taqman-based Real Time-PCR was carried out to detect all *Leptospira* species by amplifying a conserved region of the *16S rRNA* gene and discriminating pathogenic ones by the amplification of a *lipL32* gene fragment. Genotyping of *Leptospira* species was carried out by the Multi-locus sequence typing at the Italian National Reference Centre for Leptospirosis.

Two analysed wild boars were positive for pathogenic *Leptospira* species, both identified as *L. interrogans* serogroup Pomona.

This study highlights the role of wild boars as maintenance species for pathogenic *Leptospira* serogroups and, in particular, for Pomona. The intensified contacts between wild boars and domestic animals together with the continuous changes in wildlife habitat increase the risk for leptospirosis transmission and spreading to domestic animals and humans.

E-Mail of presenting author: valeria.blanda@izssicilia.it

ORGANIZATION OF ANIMAL LEPTOSPIROSIS DIAGNOSTIC STUDIES IN THE RUSSIAN FEDERATION

¹ Belousov Vasily, ¹ Varentsova Alisa, ¹ Nurlygayanova Gulnara, ² Soboleva Galina, ³ Panin Alexander

¹ FGBI "Central Scientific and Methodological Veterinary Laboratory", Moscow, Russian Federation

² LLC "Vetbiohim", Moscow, Russian Federation

³ FGBI VGNKI, Moscow, Russian Federation

Leptospirosis of animals in the Russian Federation is recorded annually in almost all federal districts, due to the existence of natural foci of the disease and the carriage of leptospira among production animals and dogs. Diagnosis of leptospirosis in animals is carried out by methods of bacteriological (including microscopic), serological (microagglutination test, ELISA) studies, as well as by PCR. In anthropurgic foci, leptospirosis affects cattle, buffaloes, pigs, horses, sheep, goats, deer, dogs, camels, cage-raised fur bearing animals and synanthropic rodents. There is an asymptomatic course of infection with subsequent leptospirosis, in some cases, abortions. When abortion occurs in animals, differential diagnosis is performed. It has been established that the excretion of leptospira in the urine after a relapse, incl. asymptomatic in animals can reach 1.5 years. This report provides analytical and statistical data on animal leptospirosis in Russia over the past three years (2018-2020). During this period, 3871136 units of animals of all species were examined. In Russia, on average, 42.3% of cattle, 39.6% of pigs, 11.6% of sheep and goats, 5.8% of horses, 0.001% of fur animals, 0.5% - dogs. Positive serological reactions were detected in 99266 (2.6%) units of the examined animals. Among the examined units, positive serological reactions to leptospira (by the microagglutination test) were detected in cattle - 4.8% of cases, in horses-5.8%, in sheep and goats-1.2%, in pigs-1.2%, fur-bearing animals-12%, dogs-3.7%. Positive serological reactions to leptospira (by ELISA) were detected in 0.7% of production animals and 5.4% of dogs. Leptospirosis was detected by the bacteriological method in cattle in 0.04%, in pigs - in 0.01%, in dogs - in 0.4% of cases. Leptospira was not detected in horses and small ruminants, including the PCR method. In the urine study by PCR, the leptospira genome was detected in 0.03% of cases, including 0.4% of cattle, 2.15% of dogs, and 6.2% of fur animals. In the study of other animal species, leptospira DNA was not detected.

The etiological structure of animal leptospirosis in Russia is as follows: leptospira of Icterohaemorrhagiae serogroup is 17.9%, Tarassovi - 11.4%, Grippotyphosa - 8.5%, Sejroe - 7.7%, Pomona - 7.6%, Hebdomadis - 7.2 %, Canicola - 3.5%. Mixed reactions are 36.2%. Most often leptospira of Icterohaemorrhagiae serogroup was detected in pigs (37-40%), horses (up to 15%) and dogs (35-40%), Canicola - in horses and fur-bearing animals, Grippotyphosa in horses and small ruminants, Hebdomadis, Sejroe and Pomona in cattle and small ruminants, Tarassovi in cattle and pigs. At present, in Russia, taking into account the achievements of science and practice, new rules for the prevention, diagnosis and control of animal leptospirosis are being developed.

E-Mail of presenting author: science@cnmvl.ru