

Submitted: 07/01/2017

Accepted: 12/04/2017

Published: 23/04/2017

Encephalomyocarditis virus in a captive Malayan tapir (*Tapirus indicus*)

Francis Vercammen^{1,*}, Leslie Bosseler², Marylène Tignon³ and Ann Brigitte Cay³

¹Centre for Research and Conservation, Royal Zoological Society of Antwerp, K. Astridplein 26, B-2018 Antwerp, Belgium

²Department of Pathology, Bacteriology and Avian Medicine, Faculty of Veterinary Medicine, University of Ghent, Salisburylaan 133, B-9820 Merelbeke, Belgium

³Department of Virology, Veterinary and Agrochemical Research Centre, Groeselenberg 99, B-1180 Brussels, Belgium

Abstract

A 5-month-old female captive Malayan tapir (*Tapirus indicus*) died suddenly without preceding symptoms. Gross necropsy revealed numerous white circular and linear foci in the myocardium. Differential diagnosis all turned out negative, except for encephalomyocarditis virus. Histopathology revealed mineralisation of myocardial cells and interstitial infiltration of lymphocytes, plasma cells and less neutrophils. Encephalomyocarditis virus was detected by PCR. Although encephalomyocarditis virus occurs in many mammals, this is the first published description of this virus in a Malayan tapir.

Keywords: Encephalomyocarditis virus, Malayan tapir, Myocardium, *Tapirus indicus*.

Introduction

The Malayan tapir (*Tapirus indicus*) is one of the four tapir species and is currently endangered with less than 2500 animals remaining in the wild and only 164 captive animals in 81 institutions worldwide (Traeholt *et al.*, 2016; Zoological Information Management System). Its major threats are habitat loss (deforestation) and increased hunting (Traeholt *et al.*, 2016).

There is no descriptive report on encephalomyocarditis virus (EMCV) in tapirs in the international literature, but the occurrence of this disease is mentioned in the Tapir (Tapiridae) Care Manual of the Association of Zoos and Aquariums (2013) and two cases were mentioned briefly by Janssen *et al.* (1996). Yet, several publications exist of EMCV in other mammal species in zoological collections (Wells *et al.*, 1989; Reddacliff *et al.*, 1997; Vogelnest *et al.*, 2006; Canelli *et al.*, 2010; Liu *et al.*, 2013; Yeo *et al.*, 2013).

The present report describes the gross necropsy, histopathology and ancillary laboratory examinations of a fatal EMCV infection in a young captive Malayan tapir. This case is the first published description of this disease in this animal species.

Case details

At the Antwerp Zoo (Royal Zoological Society of Antwerp), a young, female Malayan tapir, 5 months old, was found dead in its inside enclosure without preceding clinical abnormalities. Gross post-mortem examination revealed a normal body condition (body weight of 130 kg) and the following salient findings:

white foam in nostrils; about 1 litre abdominal serohaemorrhagic fluid containing some fibrin clots; spumeous liquid in the trachea; congestion of the lungs; large pale liver areas with central degeneration; areas of mucosal congestion in the duodenum and jejunum with a greyish to chocolate brown liquid content, but without visible blood present; congestion of the mesenteric lymph nodes; soft kidney consistency with a pale cortex; and with the most important findings was the presence of multiple white circular and linear foci of up to 0.5 cm diameter in the myocardium (Fig. 1).

A set of tissue samples (liver, lung, kidney, duodenum, jejunum, mesenteric lymph node and heart) were collected and fixed in 10% neutral buffered formalin, embedded in paraffin, sectioned at 4 µm, and stained with haematoxylin and eosin for histologic examination at the Veterinary Pathology Lab (Faculty of Veterinary Medicine, University of Ghent, Belgium).

Samples of the abnormal myocardial tissue were sent to the National Reference Lab (Veterinary and Agrochemical Research Centre, Brussels, Belgium) and to the Laboratory for Exotics (Faculty of Veterinary Medicine, University of Ghent, Belgium) for the detection of encephalomyocarditis virus and herpes virus by polymerase chain reaction (PCR). A large piece of the liver was sent to the Toxicology Lab (Faculty of Veterinary Medicine, University of Ghent, Belgium) for the detection and quantification of ionophores (maduromycin, narasin, lasalocid, monensin, salinomycin and semduramicin), vitamin E and selenium.

*Corresponding Author: Francis Vercammen. Centre for Research and Conservation, Royal Zoological Society of Antwerp, K. Astridplein 26, B-2018 Antwerp, Belgium. Tel.: +32 (0)3 202 45 48. Email: francis.vercammen@kmda.org

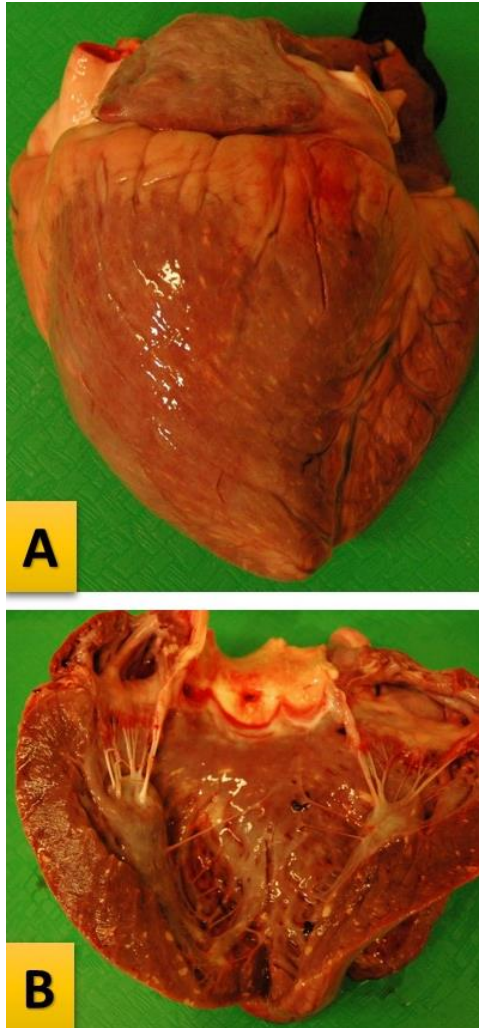


Fig. 1. Gross necropsy: Heart (A: External view; B: Internal view) of a Malayan tapir with encephalomyocarditis virus infection. Multiple circular to linear white foci (mineralisation) are present in the myocardium.

Histopathology of the lung showed diffuse mild to moderate congestion. The liver showed severe and diffuse congestion with centrilobular vacuolar degeneration. The duodenum showed severe congestion and a moderate infiltration of lymphocytes and plasma cells in its lamina propria. The lamina propria of the jejunum was mildly infiltrated with lymphocytes and plasma cells. Oedema was noticed in the mesenteric lymph nodes with the presence of blood in the subcapsular and medullary sinuses. The kidneys showed no histologic abnormalities. Multifocal large areas of myocardial cells with a diffuse basophilic granulation (mineralisation) were present. At the periphery of the mineralised areas, a few myocardial cells showed hyper eosinophilia, loss of cross-striations and nuclear pyknosis (necrosis). Surrounding the mineralised areas was interstitial infiltration of lymphocytes, plasma cells and less neutrophils (Fig. 2).

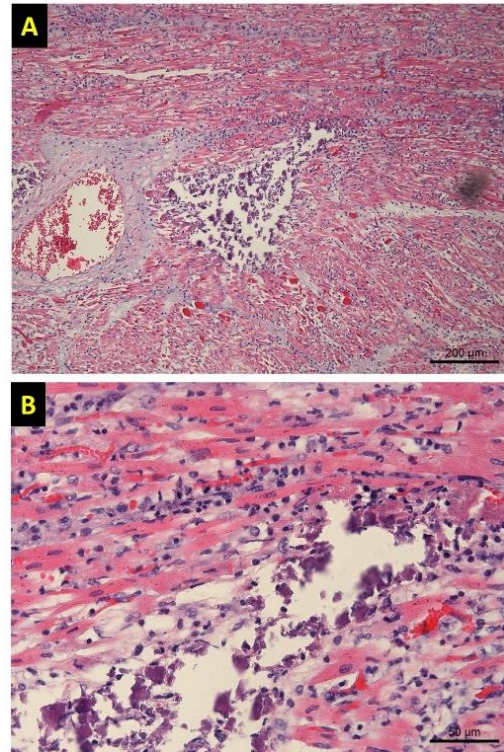


Fig. 2. Histopathology of the heart of a Malayan tapir with encephalomyocarditis virus infection. (A): Areas of basophilia (mineralisation) are surrounded by an intense interstitial inflammatory infiltrate. (B): Myocardial cells with a diffuse basophilic granulation (mineralisation), surrounded by interstitial infiltration of lymphocytes, plasma cells and a few neutrophils.

The presence of encephalomyocarditis virus was confirmed by PCR amplification of 285 nucleotides located in the 3D polymerase-coding region with primers P1 and P2 (Koenen *et al.*, 1999). The sequence of the amplicon was compared with the reference strain VR-129 (AJ235699.1), the Belgian isolate BEL-279/95 (AJ235701.1), the typical Belgian porcine myocardial strain, and a Belgian field isolate circulating in the pig herds in the same period (data not published). The alignments were performed using the alignment tool Clustal O (Goujon *et al.*, 2010). The tapir isolate presented sequence identities of 86.4%, 97.4% and 100% with the VR-129, BEL-279/95 and the simultaneously circulating Belgian porcine isolate, respectively. Herpes virus was not detected by PCR. Toxicological analysis of liver tissue was negative ($< 2 \mu\text{g}/\text{kg}$) for all examined ionophores and it contained 21.7% dry matter with 13.8 mg/kg vitamin E and 1.1 mg/kg selenium (all measurements in dry matter).

Tissue impression smears of heart, duodenum, mesenteric lymph node and liver were made for bacteriological examinations. Giemsa stain, Gram stain and Ziehl-Neelsen stain were all negative, except for the duodenum that contained a mixed flora. Cultivation

on tryptone-soya-agar, blood agar and Sabouraud agar demonstrated *Escherichia coli* and *Enterococcus* sp. in the mesenteric lymph node, *E. coli* in the liver, a mixed flora with *Clostridium* sp. in the duodenum, but there was no growth of any bacteria in the heart. In addition, the cultivation of abdominal fluid did not yield any bacteria either.

Discussion

The observations in the myocardial macroscopy (white foci) and the histopathology (mineralisation) need some differential diagnosis especially for nutritional cardiomyopathy (vitamin E / selenium deficiency), ionophores intoxication and encephalomyocarditis virus.

Vitamin E / selenium deficiency is a well-known condition in domestic and zoo animals (Valentine *et al.*, 2002; Liesegang and Baumgartner, 2004; Katz *et al.*, 2009). Vitamin E and selenium values are unknown in normal tapir liver, but reference ranges for domestic horses are 10 – 40 µg/g and 0.7 – 2.0 µg/g dry weight, respectively (Yamini and Schillhorn van Veen, 1988; Finno *et al.*, 2006; Barigye *et al.*, 2007). A Brazilian tapir (*Tapirus terrestris*) with nutritional myopathy showing pale skeletal muscles and a pale myocardium had a critically low hepatic vitamin E value of 1.3 µg/g and a normal selenium value of 1.20 µg/g dry weight (Yamini *et al.*, 1988). The authors considered the hepatic vitamin E value of 12.74 µg/g and the selenium value of 1.2 µg/g dry weight of a Quarter Horse with myocardial degeneration as suboptimal and normal, respectively (Barigye *et al.*, 2007). The tapir in the present case showed only the myocardial lesions while the skeletal muscles appeared normal with adequate hepatic dry weight values of 13.8 µg/g vitamin E and 1.1 µg/g selenium. Hence, vitamin E / selenium deficiency was excluded.

Since the toxicology lab did not find any of the ionophores that could be involved in Belgium (maduromycin, narasin, lasalocid, monensin, salinomycin, semduramicin) in the liver tissue, this possibility was also excluded.

Outbreaks of encephalomyocarditis virus are notorious for their suddenness and many cases occur as asymptomatic deaths both in zoo mammals and in young domestic pigs (Wells *et al.*, 1989; Reddacliff *et al.*, 1997; Gelmetti *et al.*, 2006; Vogelnest *et al.*, 2006; Canelli *et al.*, 2010; Yeo *et al.*, 2013). In our case, the Malayan tapir died suddenly without any predictive symptoms. The only reference in literature mentions one juvenile (1 - 4 years old) and one adult (4 - 20 years old), without specifying the tapir species, dying from EMCV during an observation period of 35 years (1960 - 1995) (Janssen *et al.*, 1996). In our case that aged 5 months, the animal was clearly much younger and more comparable to the young pigs that die due to EMCV in Belgium. Moreover, the viral sequences of our tapir

strain are identical to the porcine isolate, which was collected in the same period, and share a high (> 95%) identity with the typical Belgian porcine myocardial strain (Koenen *et al.*, 1999; Gelmetti *et al.*, 2006). Also the gross and histological lesions are comparable to the lesions described in young piglets with EMCV (Billinis *et al.*, 1999; Psychas *et al.*, 2001). Affected piglets typically show multiple circular or linear, white foci in the myocardium, excessive fluid in the pericardium, pleura and peritoneum, and pulmonary oedema. The tapir in this case showed similar myocardial lesions, peritoneal effusion, and pulmonary oedema and congestion.

Histologically, the cardiac lesions described in affected piglets consist of mainly mononuclear interstitial myocarditis, and multifocal zones of myocardial degeneration and necrosis with patchy mineralisation. The cardiac samples of the tapir in this case showed no massive myocardial degeneration and necrosis. Instead, the lesions consisted of large areas of mineralisation, minimal myocardial necrosis, and mononuclear interstitial myocarditis. However, since no other signs of hypercalcaemia were present in the tapir, the mineralisation is here interpreted to be of dystrophic nature. Why the mineralisation was so much more prominent in this case, compared to other EMCV cases, is not known.

Rodents, in particular rats and mice, are the natural hosts of encephalomyocarditis virus and excrete the virus in their faeces and urine (Quinn *et al.*, 2011). Therefore, a rigorous pest control programme is absolutely necessary and existing in our zoo. So far, the present case is still the only one that has been diagnosed in our zoo mammals, probably because of a thorough existing pest control. Whenever our zoo would experience a real epizootic, vaccination could be applied; yet, it remains unclear whether or not the vaccine will produce protective antibody titres in all the diverse zoo mammal species (Wells *et al.*, 1989; Vogelnest *et al.*, 2006).

Acknowledgements

The authors wish to thank the Flemish Government for structural support to the Centre for Research and Conservation.

Conflict of interests

The authors declare that there is no conflict of interest.

References

- Association of Zoos and Aquariums Tapir Taxon Advisory Group (AZA Tapir TAG). 2013. Tapir (Tapiridae) Care Manual. Associations of Zoos and Aquariums, Silver Spring, Maryland, USA.
- Barigye, R., Dyer, N.W. and Newel, T.K. 2007. Fatal Myocardial Degeneration in an Adult Quarter Horse with Vitamin E Deficiency. *J. Equine Vet. Sci.* 27, 405-408.

- Billinis, C., Paschaleri-Papadopoulou, E., Anastasiadis, G., Psychas, V., Vlemmas, J., Leontides, S., Koumbati, M., Kyriakis, S.C. and Papadopoulos, O. 1999. A Comparative Study of the Pathogenic Properties and Transmissibility of a Greek and a Belgian Encephalomyocarditis Virus (EMVC) for Piglets. *Vet. Microbiol.* 70, 179-192.
- Canelli, E., Luppi, A., Lavazza, A., Lelli, D., Sozzi, E., Moreno Martin, A.M., Gelmetti, D., Pascotto, E., Sandri, C., Magnone, W. and Cordioli, P. 2010. Encephalomyocarditis virus in an Italian zoo. *Viol. J.* 7, 64.
- Finno, C.J., Valberg, S.J., Wünschmann, A. and Murphy, M.J. 2006. Seasonal pasture myopathy in horses in the midwestern United States: 14 cases (1998-2005). *J. Am. Vet. Med. Assoc.* 229, 1134-1141.
- Gelmetti, D., Meroni, A., Brocchi, E., Koenen, F. and Cammarata, G. 2006. Pathogenesis of encephalomyocarditis experimental infection in young piglets: a potential animal model to study viral myocarditis. *Vet. Res.* 37, 15-23.
- Goujon, M., McWilliam, H., Li, W., Valentin, F., Squizzato, S., Paern, J. and Lopez, R. 2010. A new bioinformatics analysis tools framework at EMBL-EBI. *Nucleic Acids Res.* 38, W695-699.
- Janssen, D.L., Rideout, B.A. and Edwards, M.E. 1996. Medical management of captive tapirs (*Tapirus* spp.). *Proc. Am. Assoc. Zoo Vet.* 1-11.
- Katz, L.M., O'Dwyer, S. and Pollock, P.J. 2009. Nutritional muscular dystrophy in a four-day-old Connemara foal. *Irish Vet. J.* 62, 119-124.
- Koenen, F., Vanderhallen, H., Dickinson, N.D. and Knowles, N.J. 1999. Phylogenetic analysis of European encephalomyocarditis viruses: comparison of two genomic regions. *Arch. Virol.* 144, 893-903.
- Liesegang, A. and Baumgartner, K. 2004. Liesegang L and Baumgartner K. 2004. Selenium and vitamin E deficiency in different species over a period of 8 years. European Association of Zoo- and Wildlife Veterinarians (EAZWV), 5th scientific meeting, Ebeltoft, Denmark.
- Liu, H., Yan, Q. and He, H. 2013. Complete Nucleotide Sequence of Encephalomyocarditis Virus Isolated from South China Tigers in China. *Genome Announc.* 1, e00651-13.
- Psychas, V., Papaioannou, N., Billinis, C., Paschaleri-Papadopoulou, E., Leontides, S., Papadopoulos, O., Tsangaris, T. and Vlemmas, J. 2001. Evaluation of Ultrastructural Changes Associated with Encephalomyocarditis Virus in the Myocardium of Experimentally Infected Piglets. *Am. J. Vet. Res.* 62, 1653-1657.
- Quinn, P.J., Markey, B.K., Leonard, F.C., FitzPatrick, E.S., Fanning, S. and Hartigan, P.J. 2011. *Veterinary Microbiology and Microbial Disease.* Blackwell Publishing Ltd.
- Reddacliff, L.A., Kirkland, P.D., Hartley, W.J. and Reece, R.L. 1997. Encephalomyocarditis virus infections in an Australian zoo. *J. Zoo Wildl. Med.* 28, 153-157.
- Traeholt, C., Novarino, W., bin Saaban, S., Shwe, N.M., Lynam, A., Zainuddin, Z., Simpson, B. and bin Mohd, S. 2016. *Tapirus indicus*. The IUCN Red List of Threatened Species 2016: e.T21472A45173636. <http://dx.doi.org/10.2305/IUCN.UK.2016-1.RLTS.T21472A45173636.en>
- Valentine, B.A., Hammock, P.D., Lemiski, D., Hughes, F.E., Gerstner, L. and Bird, K.E. 2002. Severe diaphragmatic necrosis in 4 horses with degenerative myopathy. *Can. Vet. J.* 43, 614-616.
- Vogelnest, L., Hulst, F., Reiss, A. and Barnes, J. 2006. Efficacy of an inactivated vaccine in the prevention of encephalomyocarditis virus infection in chimpanzees (*Pan troglodytes*) and other species. *Proc. Am. Assoc. Zoo Vet.* 164-167.
- Wells, S.K., Gutter, A.E., Soike, K.F. and Baskin, G.B. 1989. Encephalomyocarditis virus: epizootic in a zoological collection. *J. Zoo Wildl. Med.* 20, 291-296.
- Yamini, B. and Schillhorn van Veen, T.W. 1988. Schistosomiasis and Nutritional Myopathy in a Brazilian Tapir (*Tapirus terrestris*). *J. Wildl. Dis.* 24, 703-707.
- Yeo, D.S-Y., Lian, J.E., Fernandez, C.J., Lin, Y-N., Liaw, J.C-W., Soh, M-L., Lim, E. A-S., Chan, K-P., Ng, M-L., Tan, H-C., Oh, S., Ooi, E-E. and Tan, B-H. 2013. A highly divergent Encephalomyocarditis virus isolated from nonhuman primates in Singapore. *Viol. J.* 10, 248.